J Oral Maxillofac Surg
41:351-357, 1983

A New Concept in the Treatment of Osteoradionecrosis

ROBERT E. MARX, DDS*

Hyperbaric oxygen and aggressive surgery in a progressively staged manner were used to achieve complete resolution of osteoradionecrosis of the mandible in 58 patients. Forty-one patients required partial mandibulectomy. All the discontinuous mandibles were reconstructed, and function was restored in all patients.

Both surgical and nonsurgical treatments have been used for osteoradionecrosis of the jaws.[1-3] Nonsurgical treatments have been falsely described as "conservative therapy." Rankow and Weissman[3] recommended treatment of osteoradionecrosis of the jaws in two stages. Patients were advised to avoid alcohol, smoking, hot and cold foods, and prosthodontic appliances; tetracycline, a variety of oral rinses, and analgesics were routinely prescribed. After one year, if exposed bone persisted, pain continued, a pathologic fracture developed, or an orocutaneous fistula formed, then hemimandibulectomy was performed. The result was a high incidence of nonresponders who came to surgery after the year's course of treatment and required more extensive resections than would have initially been indicated. Rankow and Weissman estimated that 25% of their patients were nonresponders, but in another report by Daly and Drane,[4] 64% of patients represented failure of nonsurgical therapy.

Conservative surgical approaches have also been proposed. Hahn and Corgill[5] drilled holes through the irradiated nonviable mandibular cortex into viable medullary bone in order to stimulate granulation tissue to proliferate over or replace the necrotic bone. The outcome of this approach, also, was often resection, but not before many months of continued disease (Fig. 1). Lengthy courses of antibiotic and analgesic therapy, to the point of iatrogenic addiction, are also common. Often, practitioners also perform repeated sequestrectomies with rongeurs or burrs, resulting only in larger areas of exposed bone, the cumulative removal of large segments of mandible, and failure to control the disease process.

The single most important reason nonsurgical and conservative surgical approaches are associated with such statistically poor results is that they fail to address the basic pathophysiology of the disease.[6] Tetracycline or other antibiotic therapy continued for long periods of time without significant repair of the exposed bone suggests a limited response to antimicrobial treatment. Either the antibiotic is ineffective against the organisms present, or, as we know now, organisms are not a major factor in the progression of the disease.[6] On the other hand, prolonged periods of unsuccessful treatment often result in extension of the disease. An area of irradiated bone and mucosa that breaks down, whatever the cause, has a much greater oxygen and metabolic demand than it had prior to being wounded. To allow a year or more to proceed, or to intervene with holes or sequestrectomies, adds a further demand for oxygen and nutrition to the tissues. Further cellular death and collagen lysis ensue, resulting in a wider area of mucosal breakdown and a greater quantity of nonviable bone. With such a loss of time and tissue, resections must be larger than would have earlier been required. Furthermore, these approaches have a built-in loss of human and financial resources, as well as a potential for causing drug addiction. The unproductive hours spent in wound care, and the quantity of antibiotics and narcotic analgesics prescribed for a single case of osteoradionecrosis in a year's time, are astronomical.

Hyperbaric oxygen has been reported[6,7] to be effective as an adjunctive treatment for osteoradionecrosis. It was thought that hyperbaric oxygen was directly bacteriostatic or bacteriocidal and that it increased oxygen-dependent leukocyte microbial

* Lieutenant Colonel, USAF, DC; Assistant Chairman, Department of Oral and Maxillofacial Surgery, and Director of Dental Research, Wilford Hall USAF Medical Center, Lackland AFB, Texas.

The opinions contained in this article are those of the author and are not to be construed as official or as reflecting the view of the United States Air Force of the Department of Defense.

Address correspondence and reprint requests to Dr. Marx: Department of Oral/Maxillofacial Surgery, Wilford Hall USAF Medical Center/SGDO, Lackland AFB, TX 78236.

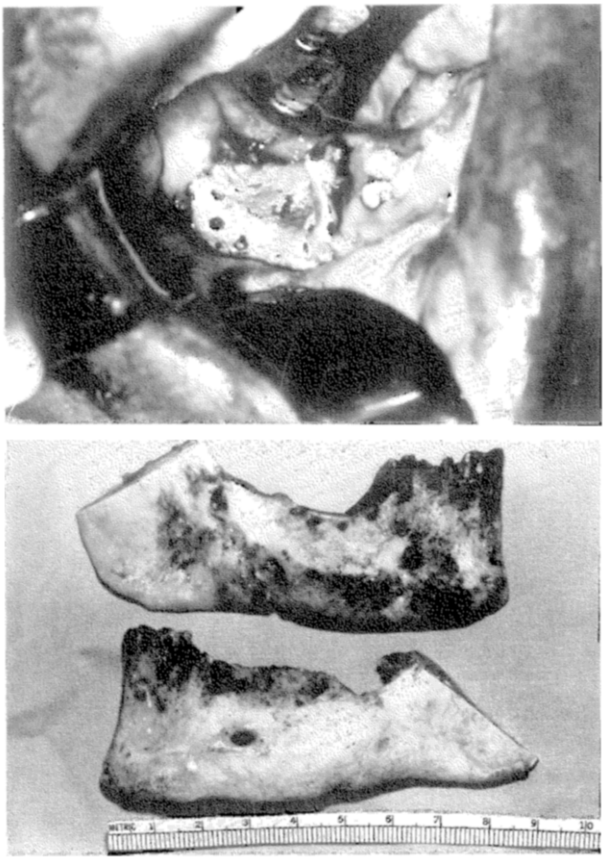

FIGURE 1. *Above,* Persistent osteoradionecrosis six months after placement of bur holes into medullary bone. *Below,* Same mandible after 22 months of persistent exposed bone. Notice sockets in anterior mandible with no evidence of remodeling after 28 months.

killing properties.[9-11] Hart and Mainous[8] also suggested as early as 1976 that the action of hyperbaric oxygen may be due not to its antibacterial effects but to an enhancement of wound healing through vascular proliferation. Nevertheless, hyperbaric oxygen was reported to relieve pain, eliminate orocutaneous fistulas, and achieve osseous union in pathologic fractures.[11]

Many practitioners saw hyperbaric oxygen as the definitive cure for osteoradionecrosis and were disappointed when less than absolute cures were observed. Some of the unsatisfactory results were caused by different protocols for hyperbaric oxygen time and depth as well as by differences in the amount and timing of surgical intervention. Surgery was employed very sparingly in the reported patient series. Mainous et al[12] reported adjunctive surgical procedures in 14 patients, and in a second report,[7] in 19 of 46 patients. Small sequestrectomies represented the most common surgical procedure.[7,12] Reconstruction of resected mandibles was rarely reported. (Only four of 46 patients in the series by Mainous and Hart[7] and only one of 14 in the series by Mainous and Boyne,[12] underwent mandibular reconstructions.)

Several reports discussed arrest of disease, not resolution of disease.[8,13] Patients were reported to require two or more courses of hyperbaric oxygen, accumulating 120 to 150 hours or more of exposure.[12] Indeed, our experience at Wilford Hall USAF Medical Center was also one in which many patients would undergo hyperbaric oxygen therapy and experience improvement but not complete healing of the exposed bone. They all experienced pain relief but were discharged with persistently exposed bone after 80 to 120 hours of treatment. They all returned later with further exposed bone and a recurrence of pain. Many of our patients underwent several courses of hyperbaric oxygen, but the condition only remained temporarily arrested between hyperbaric oxygen courses. Some patients accumulated up to 350 hours of hyperbaric oxygen exposure. Our experience and that of others soon established that hyperbaric oxygen without aggressive surgical management would not resolve the disease process in most cases. The inability of practitioners and institutions to reproduce the reported results and touted accomplishments of hyperbaric oxygen, such as the repair of nonunions without grafting, and the healing of orocutaneous fistulas without surgical closure, gave pause to its wide acceptance as a primary treatment modality. Yet, it is well known that hyperbaric oxygen enhances wound healing,[14,15] a property that addresses the basic pathophysiology of osteoradionecrosis.[6]

The overview is that nonhyperbaric oxygen approaches are unable to improve osteoradionecrosis consistently. Hyperbaric oxygen alone is able to arrest osteoradionecrosis but cannot totally resolve it. The result is a waste of time and expense with extensive treatment courses and excessive hyperbaric oxygen exposure.

The challenges in the effective application of hyperbaric oxygen are these:

1. To identify patients who can respond to hyperbaric oxygen without aggressive surgery.
2. To know when to intervene with surgery.
3. To determine what degree of surgical intervention is required.
4. To provide reconstruction to all those who require resection.
5. To coordinate hyperbaric oxygen with surgery to resolve osteoradionecrosis and not merely arrest its progress.
6. To keep hyperbaric oxygen exposures to a minimum.

To meet these challenges, we have developed a definitive hyperbaric oxygen protocol based on the

Table 1. Refractory Osteoradionecrosis

Previous Treatment Modality	Total No. of Patients	No. with Orocutaneous Fistulas	No. with Pathologic Fracture	No. with Pain
Nonsurgical	23	4	6	11
Surgical without hyperbaric oxygen	8	1	2	7
Surgical with hyperbaric oxygen	5	0	0	3
Hyperbaric oxygen alone	22	6	6	12
Total	58	11	11	33

pathophysiology elucidated in our previous report.[6] This protocol was investigated at Wilford Hall USAF Medical Center and represents a new concept in the treatment of osteoradionecrosis.

Materials and Methods

Fifty-eight patients who were referred to Wilford Hall USAF Medical Center with a diagnosis of "refractory osteoradionecrosis" were treated with this investigational protocol. All 58 had persistent osteoradionecrosis after treatment by nonsurgical, surgical, or other hyperbaric oxygen protocols. A summary of the previous treatment approaches and complicating factors is presented in Table 1.

Patients received hyperbaric oxygen in a multiplace chamber at either the USAF School of Aerospace Medicine, Brooks Air Force Base, Texas, or Methodist Hospital, Department of Hyperbaric Medicine, San Antonio, Texas. Both facilities achieve a controlled hyperbaric oxygen delivery cycle, or "dive." Each dive consists of

FIGURE 2. *Above,* Osteoradionecrosis before patient entered Stage I of Wilford Hall USAF Medical Center protocol. *Below,* Resolution of osteoradionecrosis after Stage I therapy.

1. 100% oxygen breathed via a pilot's face mask or plastic hood.
2. Chamber compression to 2.4 atmospheres absolute pressure (ATA).
3. Oxygen exposure for 90 minutes, once per day, five days per week.

The Wilford Hall hyperbaric oxygen osteoradionecrosis protocol consists of three stages.

In Stage I, there are 30 dives, after which the osteoradionecrosis wound is re-examined. If the wound shows definitive clinical improvement, such as a decrease in the amount of exposed bone, granulation tissue covering the exposed bone, resorption of nonviable bone, and absence of inflammation, the patient completes a full course of 60 dives for achievement of full mucosal cover (Fig. 2). If there is no clinical improvement by 30 dives, as evidenced by extended or continued exposure of bone, absence of mucosal proliferation, or presence of inflammation, the patient is identified as a nonresponder to Stage I and is advanced to Stage II.

In Stage II, a transoral alveolar sequestrectomy is accomplished with a primary mucosal closure. Hyperbaric oxygen dives continue after surgery. If healing progresses without complication, dives continue up to a total of 60 (Fig. 3). If the wound dehisces, leaving exposed bone, the patient is identified as a nonresponder to Stage II and is advanced to Stage III. In a patient whose initial presentation includes either pathologic fracture, orocutaneous fistula, or radiographic evidence of resorption to the inferior border, an initial course of 30 dives is given, and the patient directly enters Stage III of treatment.

In Stage III, after a minimum of 30 dives, the patient undergoes a resection, the margins of which are determined at the time of surgery by the presence of bleeding bone or by tetracycline fluorescence under ultraviolet light. The segments of mandible are stabilized with either extraskeletal pin fixation or maxillomandibular fixation. If there is any oral dehiscence or orocutaneous fistula, de-epithelialization and primary closure are done. Hyperbaric

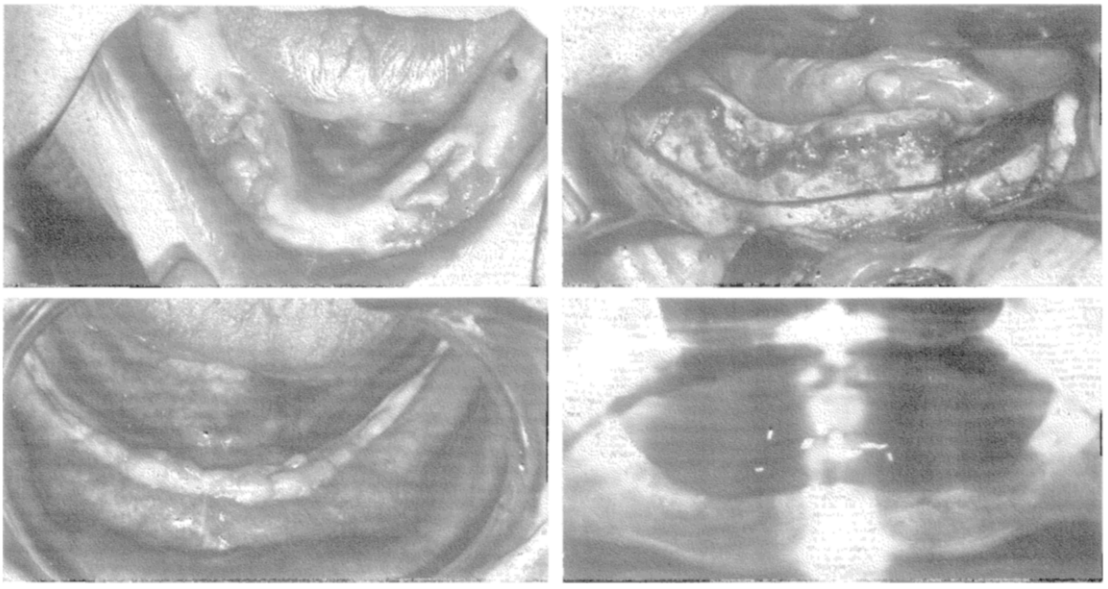

FIGURE 3. *Above, left,* osteoradionecrosis that did not respond to Stage I therapy. *Above, right,* transoral alveolar resection as part of Stage II therapy. *Below, left,* healed mucosa after Stage II therapy. *Below, right,* radiograph of mandible after Stage II therapy, showing structural integrity and quantity of remaining bone.

dives are continued until a healthy mucosal closure is evident or a total of 60 accumulated dives is reached. Patients are then advanced to Stage III-R (Figs. 4 and 5).

In Stage III-R, ten weeks after resection, the patient is given an additional 20 dives in preparation for bone graft reconstruction. Reconstruction is then accomplished from a strictly transcutaneous approach without oral contamination. Then, ten more dives are given, and jaw fixation is maintained for eight weeks. If a quantitative soft tissue deficiency exists, it is corrected by a myocutaneous or myomucosal flap prior to reconstruction in the Stage III-R profile.

Results

All 58 cases of refractory osteoradionecrosis resolved within the three stages of this protocol. The four criteria of resolution were as follows:

1. Freedom from pain.
2. Retention or reconstruction of mandibular continuity.

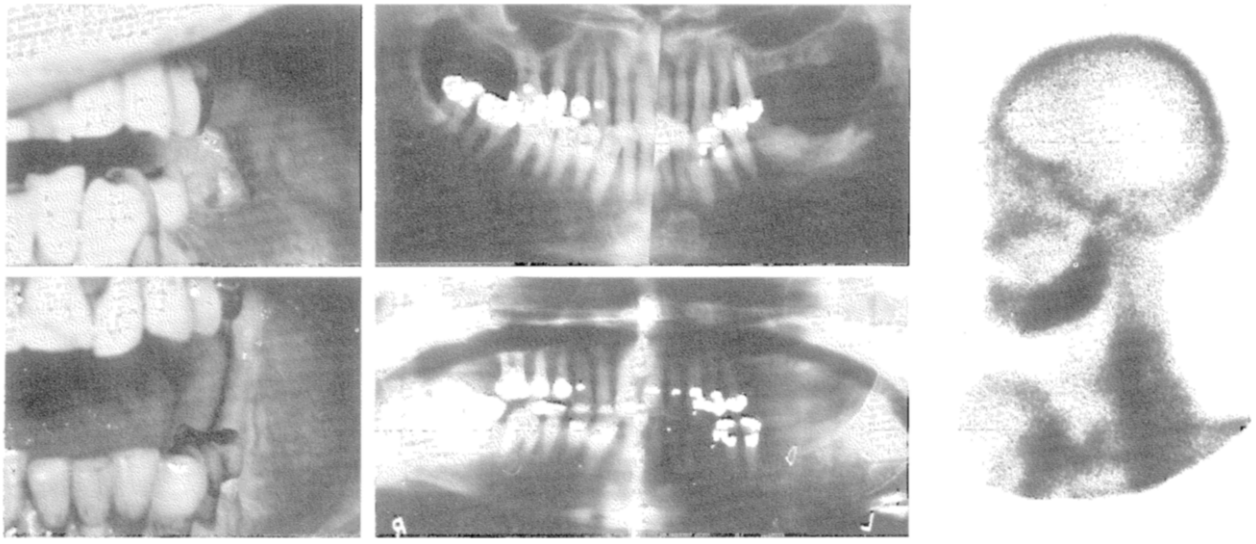

FIGURE 4. *Above, left,* Clinical view of osteoradionecrosis presenting in Stage III after 7600 rads of external beam supervoltage radiation. *Above, center,* Panoramic view of same patient, showing osteolytic process into ramus. *Below, left,* Clinical view of same area after Stage III therapy and reconstruction in Stage III-R. *Below, center,* Panoramic radiograph of same patient after Stage III therapy and reconstruction in Stage III-R. *Right,* Technetium 99 Diphosphonate bone scan of same patient, showing viability of graft.

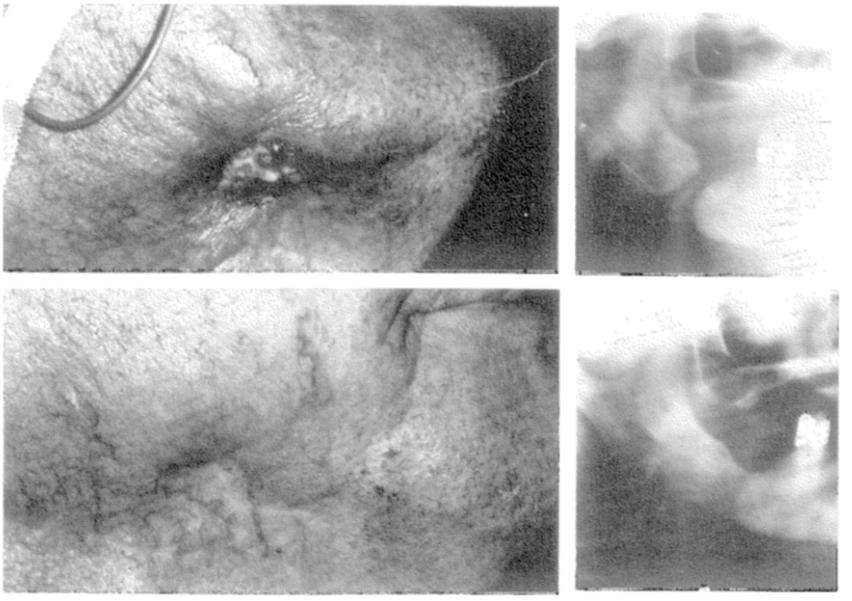

FIGURE 5. *Above, left,* Clinical view of patient with osteoradionecrosis, pathologic fracture, and an orocutaneous fistula presenting in Stage III five years after 7200 rads of combined implant external beam radiation. *Above, right,* Panoramic radiograph of same patient. *Below, left,* Clinical view of well-healed tissue after response to Stage III therapy and Stage III-R reconstruction. *Below, right,* Panoramic radiograph 36 months later. Patient had been using a partial denture since the third month after reconstruction.

3. Restoration of mandibular function and wearing of prosthodontic appliances, if needed.

4. Maintenance of intact mucosa over all bone for the length of follow-up (minimum acceptable time, 18 months). Resolution was achieved in Stage I for nine patients (15%), in Stage II for eight patients (14%), and in Stage III for 41 patients (70%) (Table 2). All 41 patients who required resection after resolution in Stage III underwent successful reconstruction with the Stage III-R protocol. These 41 reconstructions have met our published criteria for successful reconstruction,[16] i.e., restoration of continuity, restoration of alveolar bone height, elimination of soft tissue deficiencies, restoration of osseous bulk, maintenance of osseous content without resorption for a minimum of 18 months, and restoration of acceptable facial form.

Resolution occured in all patients with one course of hyperbaric oxygen exposure. Stage I and Stage II responders required 90 hours of hyperbaric oxygen. Stage III responders received an average of 108 hours of treatment (90 hours to a maximum of 135 hours). This total includes the 45 hours of hyperbaric oxygen associated with the reconstruction.

Table 2. Resolution of 58 Cases of Refractory Osteoradionecrosis

Stage of Resolution	No. of Patients	Average Time of Hyperbaric Oxygen Exposure (Hours)
Stage I	9	90
Stage II	8	90
Stage III	41	108*

* Includes hours of hyperbaric oxygen exposure accumulated for reconstruction in Stage III-R.

Discussion

The successful treatment of advanced osteoradionecrosis using aggressive surgical principles and hyperbaric oxygen may be explained by the alteration of the existing hypoxia, hypocellularity, and hypovascularity (the three H principle). Studies by Silver[17] and by Sheffield et al[18] have shown tissue oxygen tensions to be dramatically elevated during hyperbaric oxygen dives. When the dive characteristics outlined in this paper are used, wound oxygen tensions rise to 150–250 mm Hg at depth. Although wound oxygen tensions return toward hypoxic levels quickly upon ascent to sea-level/room-air breathing (10–15 mm Hg), the intermittent elevations in tissue oxygen tensions stimulate collagen synthesis and fibroblastic proliferation.[17] Hunt[19] has shown the response to new collagen synthesis to be one of vascular proliferation, the result being one of a hyperbaric oxygen-induced angiogenesis and neocellularity of the osteoradionecrotic wound. Additionally, implanted oxygen electrodes and transcutaneous oxygen monitoring have shown an improvement in tissue hypoxia toward normal oxygen levels, peaking between the 20th and 30th dives. However, hyperbaric oxygen alone cannot usually heal osteoradionecrotic wounds (only 15% of our patients responded in Stage I). The reasons are threefold. First, the degree of radiation tissue injury varies greatly between patients, even with identical doses and fractionations. Therefore, the degrees of hypoxia, hypocellularity, and hypovascularity also vary and are impossible to predict. Some patients have a greater residual and peripheral cellular pool that can respond to hyperbaric oxygen. Second, improvements we have observed in wound oxygen

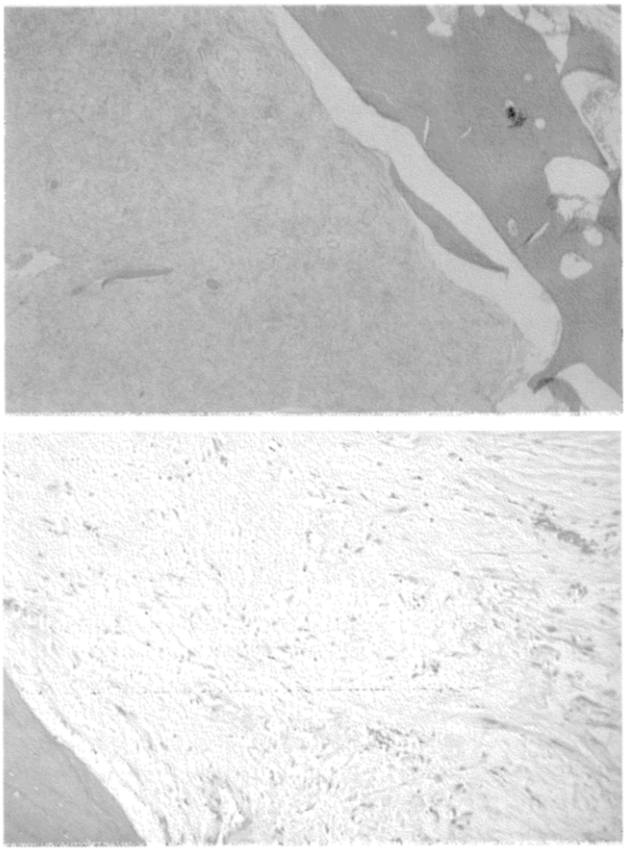

FIGURE 6. *Above*, Osteoradionecrosis specimen, showing fibrosis, hypocellularity, and hypovascularity. (Hematoxylin and eosin, original magnification ×25.) *Below*, Same patient's recipient tissue bed at time of Stage III-R reconstruction, showing hyperbaric oxygen–induced cellularity and angiogenesis. (Hematoxylin and eosin, original magnification ×25).

tensions have been toward normal oxygen levels but still do not reach those levels. Stated simply, hyperbaric oxygen cannot entirely reverse radiation injury. Third, hyperbaric oxygen cannot resurrect dead bone. In osteoradionecrosis, a certain amount of necrotic bone remains unresorbed due to the hypovascularity. Because osteoclasts have now conclusively been shown to be derived from circulating monocytes, the reason for unresorbed and nonhealing bone in osteoradionecrosis are quite apparent.[20]

The weakness of treatment not utilizing hyperbaric oxygen is that wound healing cannot progress without improvement in tissue oxygenation. This is particularly true when tissue oxygen demand is increased by surgical wounding or continuous long-term exposure of bone. Hyperbaric oxygen is the only modality that can accomplish this and should be a primary part of all therapy for osteoradionecrosis (Fig. 6).

The weakness inherent in nonsurgical approaches, even when hyperbaric oxygen is used, is that significant amounts of necrotic tissue impair wound healing. Despite the angiogenesis and cellular proliferation induced by hyperbaric oxygen, most wounds of osteoradionecrosis contain so great a quantity of necrotic bone that resorption and complete healing cannot occur. In this study, 85% of patients required some surgical removal of bone, and 71% of all patients required large resections. Debridement of necrotic tissue is a time-honored surgical principle in wounds secondary to small vessel disease. Since the pathophysiology we defined involves radiation-induced small vessel disease, the application of wound debridement is only logical. Although many others have employed wound debridement, it has often been far too little, leaving residual necrotic tissue and resulting in a more severe problem. When larger resections with adequate removal of all necrotic tissue have been employed, reconstruction has been rarely accomplished. Patients proceed with resolved osteoradionecrosis but with unacceptable functional impairment and deformity.

The merits of this protocol rest with the interrelationship of hyperbaric oxygen and surgery in a progressive sequence. Both are used for diagnostic and prognostic modalities, as well as for treatment modalities. The response of osteoradionecrosis to hyperbaric oxygen in Stage I gives a diagnostic impression of the person's actual local radiation injury. The response also gives a reasonably reliable prognostic impression as to whether resolution is possible with hyperbaric oxygen alone or whether surgery is indicated. The response of patients to Stage II therapy gives similar diagnostic and prognostic impressions, as well as definitive indications for resection.

Successful reconstruction and healing of surgical wounds were achieved within a relatively short time in every patient requiring resection who was in the Stage III and Stage III-R groups. The brief delay after Stage III resection permitted a graft to be placed into a vascular and cellular recipient bed covered with an intact mucosa. Graft infection and wound dehiscence were significantly reduced, and prosthodontic rehabilitation, when required, was possible within three months.

This protocol does not exclude the adjunctive use of antibiotics, irrigation, local wound care, and nutritional support, which are important parts of total patient care. In the past, those measures were the primary focus of therapy for osteoradionecrosis, with hyperbaric oxygen and surgery being adjunctive measures. However, our treatment results strongly suggest that hyperbaric oxygen and surgery should be the primary treatment modalities for osteoradionecrosis and that all others are adjunctive to those two.

References

1. Marchetta FC, Sako K, Holyoke DE: Treatment of osteoradionecrosis by intraoral excision of the mandible. Surg Gynecol Obstet 125:1003, 1967.
2. Robinson DW, Masters FW, Ketchum LD: Management of osteoradionecrosis. JAMA 217:950, 1971.
3. Rankow RM, Weissman B: Osteoradionecrosis of the mandible. Ann Otol Rhinol Laryngol 80:603, 1971.
4. Daly TE, Drane JB: Management of teeth related to the treatment of oral cancer. National Cancer Conference Proceedings 7. New York, American Cancer Society, 1973, p. 147.
5. Hahn G, Corgill DA: Conservative treatment of radionecrosis of the mandible. Oral Surg 24:707, 1967.
6. Marx RE: Osteoradionecrosis: A new concept of its pathophysiology. J Oral Maxillofac Surg 41:283, 1983.
7. Mainous EG, Hart GB: Osteoradionecrosis of the mandible: Treatment with hyperbaric oxygen. Arch Otoloaryngol 101:173, 1975.
8. Hart GB, Mainous EG: The treatment of radiation necrosis with hyperbaric oxygen. Cancer 37:2580, 1976.
9. Hamblen DL: Hyperbaric oxygenation: Its effects on experimental staphyloccocal osteomyelitis in rats. J Bone Joint Surg 50-A:1129, 1968.
10. McAllister TA: Inhibitory effects of hyperbaric oxygen on bacteria and fungi. Lancet 2:1040, 1963
11. Hohn DC: Oxygen and leukocyte microbial killing, *in* Davis JC, Hunt TK (eds): Hyperbaric Oxygen Therapy. Bethesda, Undersea Medical Society, Inc, 1977, p. 101
12. Mainous EG, Boyne PJ: Hyperbaric oxygen in total rehabilitation of patients with mandibular osteoradionecrosis. J Oral Surg 32:297, 1974
13. Mansfield MJ, Sanders DW, Heimbach RD, Marx RE: Hyperbaric oxygen as an adjunct in the treatment of osteoradionecrosis of the mandible. J Oral Surg 39:585, 1981
14. Ninikowski S: Effect of oxygen supply on wound healing and formation of experimental granulation tissue. Acta Physiol Scand 78 (Suppl 334):1, 1970
15. Hunt TK, Pai MD: The effect of varying ambient oxygen tensions on wound metabolism and collagen synthesis. Surg Gynecol Obstet 135:561, 1972
16. Marx RE, Ames JR: The use of hyperbaric oxygen therapy in bony reconstruction of the irradiated and tissue-deficient patient. J Oral Maxillofac Surg 40:412, 1982
17. Silver IA: The measurement of oxygen tension in healing tissue, *in* Herzog H (ed): Progress in Respiratory Research. Basel, S Karger, p 124, 1969
18. Sheffield PJ, Workman WT: Continuous tissue oxygen monitoring of hyperbaric oxygen therapy patients by the transcutaneous method. Sixth Annual Conference on Clinial Application of Hyperbaric Oxygen, Long Beach, California, June 10–12, 1981
19. Hunt TK, Federfeldt B, Goldstick TK: Oxygen and healing. Am J Surg 118:521, 1969
20. Bonucci E: New knowledge on the origin, function and fate of osteoclasts. Clin Orthop Rel Res 158:252, 1981